

# Circulation

JOURNAL OF THE AMERICAN HEART ASSOCIATION



## Supraventricular Tachycardia

Paul J. Wang and N. A. Mark Estes, III

*Circulation* 2002;106:e206-e208

DOI: 10.1161/01.CIR.0000044341.43780.C7

Circulation is published by the American Heart Association, 7272 Greenville Avenue, Dallas, TX 75214

Copyright © 2002 American Heart Association. All rights reserved. Print ISSN: 0009-7322. Online ISSN: 1524-4539

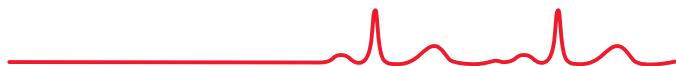The online version of this article, along with updated information and services, is located on the World Wide Web at:

<http://circ.ahajournals.org/cgi/content/full/106/25/e206>

Subscriptions: Information about subscribing to *Circulation* is online at  
<http://circ.ahajournals.org/subscriptions/>

Permissions: Permissions & Rights Desk, Lippincott Williams & Wilkins, a division of Wolters Kluwer Health, 351 West Camden Street, Baltimore, MD 21202-2436. Phone: 410-528-4050. Fax: 410-528-8550. E-mail:  
[journalpermissions@lww.com](mailto:journalpermissions@lww.com)

Reprints: Information about reprints can be found online at  
<http://www.lww.com/reprints>



## Supraventricular Tachycardia

Paul J. Wang, MD; N.A. Mark Estes III, MD



The heart is a 4-chambered muscle that functions as a blood pump; the 2 upper chambers are called the atria and the 2 lower chambers are the ventricles. The rhythm of the heart is normally controlled by a natural pacemaker (the sinoatrial node) in the right upper chamber that beats about 60 times per minute at rest and can increase with exercise. Electrical impulses travel from the natural pacemaker through the atria, then pass through a filter called the atrioventricular node (AV) between the atria and ventricles before running down specialized fibers that activate the ventricles. (Figure 1)

The atria are above the ventricles, hence the term supraventricular. The term tachycardia refers to a rapid heartbeat of over 100 beats per minute. Supraventricular tachycardia is frequently abbreviated as SVT (formerly paroxysmal atrial tachycardia or PAT). Supraventricular tachycardia then is a rapid rhythm of the heart that begins in the upper chambers. When patients experience change in the normal sequence of electrical impulses and an abnormal heart rhythm occurs, they are said to be having an arrhythmia.

### Symptoms During Supraventricular Tachycardia

- Palpitations
- Lightheadedness

- Dizziness
- Loss of consciousness
- Chest pain
- Shortness of breath

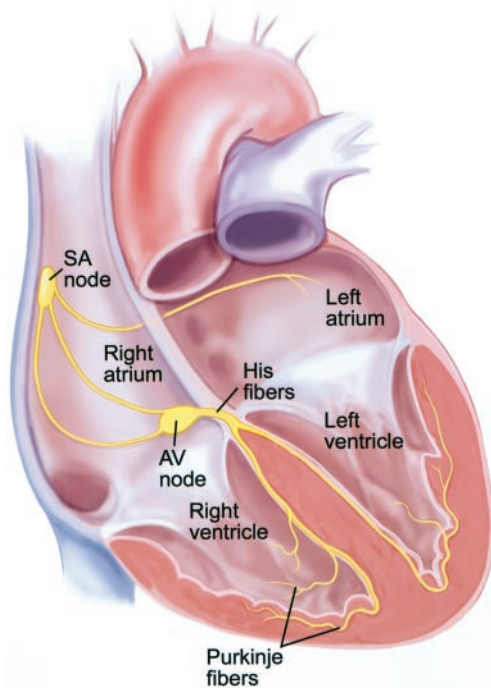
Typically, patients have symptoms from SVT, but occasionally they may have no symptoms. A common symptom during SVT is palpitations or a sensation that the heart is beating rapidly, fluttering, or racing. This may last for a few seconds or several hours. Occasionally, patients may have a sensation of shortness of breath or “air-hunger,” or chest pressure or pain. Sometimes patients will feel lightheaded or dizzy, and rarely patients will feel like they are about to pass out. Loss of consciousness (also known as syncope) during SVT is a rare occurrence. Although such symptoms may raise concern, in general, SVT is not a serious or life-threatening condition. Nonetheless, if any of these symptoms develops, immediate medical attention should be sought.

### How Is Supraventricular Tachycardia Diagnosed?

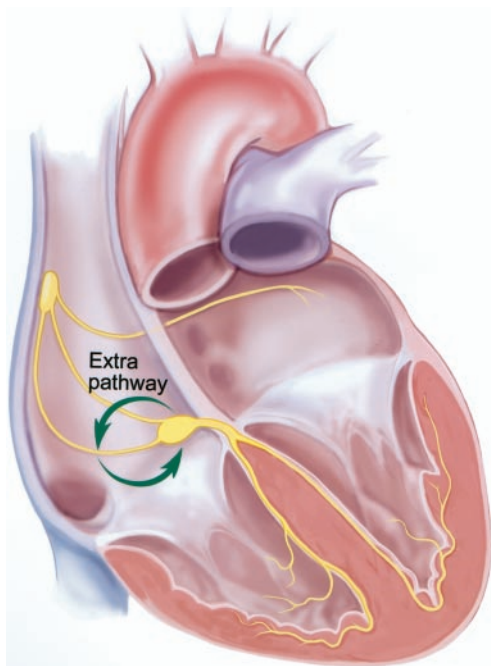
The electrocardiogram (ECG or EKG) provides a picture of the heart rhythm and is recorded by placing adhesive or gel pads on the chest and limbs. If the patient is experiencing SVT during the ECG, a clear diagnosis can be made. Various other types of electrocardiographic monitors may be used to record

the patient’s heart rhythm to help make a diagnosis of SVT. A 24-hour ambulatory Holter monitor may be used to record the heart rhythm continuously for 24 hours. This type of monitor is particularly helpful in documenting asymptomatic or very frequent rhythm abnormalities. For those patients whose arrhythmias occur relatively infrequently, event or loop monitors may be worn. An event monitor is attached to the patient’s wrist or chest whenever symptoms suggesting SVT occur. Activating a button on the monitor will start a recording of the heart’s rhythm. The patient is given instructions about how to download this information to a computer that stores results for later analysis via a special device placed over a telephone mouthpiece. For patients who experience very brief arrhythmias or those accompanied by severe lightheadedness, an event monitor is impractical. In such cases, patients may wear a loop monitor continuously for days to weeks. The loop monitor continuously records the heart’s rhythm so that the patient need only press a button to save a record of the rhythm during the preceding and subsequent 1 to 2 minutes. This permits recording even very transient arrhythmias. The loop monitor record is downloaded using a tele-

From Tufts University School of Medicine and Tufts New England Medical Center, Boston, Mass. Correspondence to Paul J. Wang, MD, Tufts New England Medical Center, 750 Washington St, Boston, MA 02111. E-mail Pwang1@lifespan.org (*Circulation*. 2002;106:e206-e208.) © 2002 American Heart Association, Inc.



**Figure 1.** Diagram of the heart and the electrical conduction system of the heart. Electrical impulses start in the sino-atrial node and travel via the atria to the AV node. From there, the electrical impulse travels through the His fibers and the Purkinje fibers to the left and right ventricles.



**Figure 2.** Diagram of AV nodal reentrant tachycardia (AVNRT). The electrical impulse travels in a circle using extra fibers in and around the AV node.

phone in the same way that event monitor data are transmitted.

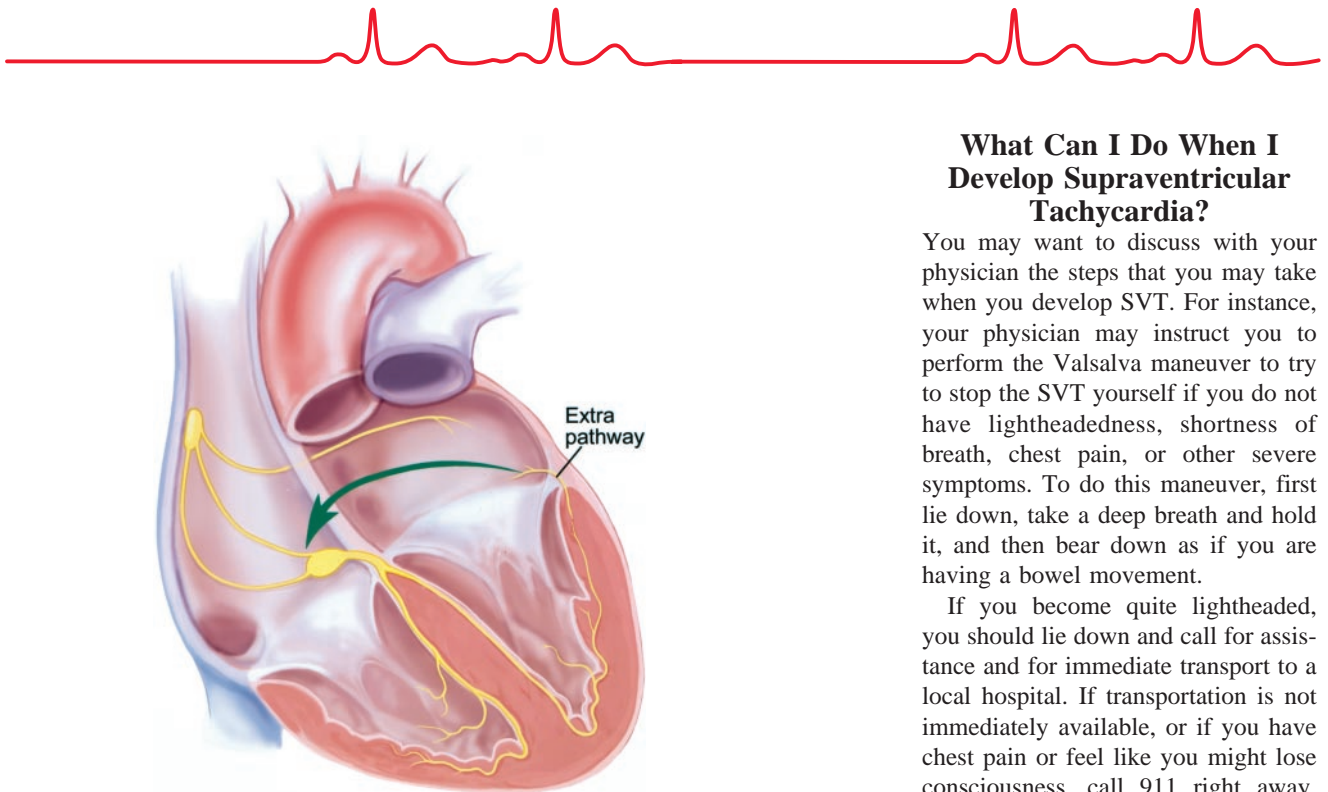
### How Is Supraventricular Tachycardia Classified?

An SVT is classified medically on the basis of the path that the electrical signal takes from the atria. One type of SVT (AV nodal reentrant tachycardia or AVNRT) occurs because the electrical impulse travels in a circle using extra fibers in and around the AV node (Figure 2). Another type of SVT occurs because of electrical conduction via extra fibers between the atria and ventricles; this means of conduction is called a bypass tract or accessory pathway. The electrical impulse travels down the AV node to the ventricle and back to the atrium via these extra fibers, producing the SVT called AV reentrant tachycardia, or AVRT (Figure 3). Some patients are told that they have Wolff-Parkinson-White Syndrome (WPW), in which there is evidence of conduction via an accessory pathway from the atrium to the ventricle that may be detected on the ECG even if they are not experiencing SVT. Atrial tachycardias occur when localized regions in the atria develop the ability to fire rapidly on their own.

### How Is Supraventricular Tachycardia Treated?

Medications may be used to treat many patients with SVT. The most commonly used classes of medications are:

- $\beta$ -blockers: These are commonly used to treat high blood pressure and other heart problems such as angina. In SVT, they are used specifically to decrease conduction through the AV node (Figure 1) to stop conduction during the tachycardia.
- Calcium channel blockers: These are also used to treat high blood pressure and heart problems. Like  $\beta$ -blockers, they may be used to decrease conduction through the AV node. Examples of calcium channel blockers include verapamil or diltiazem.
- Antiarrhythmic agents: These agents are used to treat various arrhythmias and



**Figure 3.** A diagram of AV reentrant tachycardia (AVRT). The electrical impulse travels down the AV node to the ventricles and back to the atrium via extra fibers that connect the atria and ventricles.

directly affect the atrial or ventricular heart tissue. They are most useful in SVTs that use an accessory pathway or bypass tract or in atrial tachycardias.

You will want to discuss with your physician the medical therapy that is right for you.

A special procedure called radiofrequency ablation (RFA) has been developed as an alternative to medication to treat many patients with SVT. During this procedure, special plastic tubes called catheters are inserted into a vein into the upper leg/groin area and are advanced to the heart using a fluoroscope. The catheters are used to record electrical signals from inside the heart. They can locate precisely the site from which the SVT originates. Radio waves (called radiofrequency energy) are delivered at the tip of this catheter to the precise location of the SVT, creating a small coagulation of the tissue approximately 2 mm in diameter. The procedure has a 90% to 95% chance of successfully treating the SVT, so that it does not recur or require medication. There is approxi-

mately a 5% chance that the SVT will recur, usually within the first 1 to 2 months.

RFA can carry the risks described below:

- Less than 1% risk of serious or life-threatening complications
- Less than 1% risk of damage to the normal conduction system
- Bleeding, bruising, or infection at catheter insertion site
- Damage to the heart, lungs, blood vessels, or nerves
- Blood clots to the lungs
- Need for electrical shock to the chest
- Rashes
- Allergic reactions
- Adverse effects of sedatives or anesthetic agents, such as respiratory depression requiring insertion of a breathing tube

Your cardiologist will discuss the complications and benefits of RFA with you and let you know if it is an appropriate treatment for your medical condition.

### What Can I Do When I Develop Supraventricular Tachycardia?

You may want to discuss with your physician the steps that you may take when you develop SVT. For instance, your physician may instruct you to perform the Valsalva maneuver to try to stop the SVT yourself if you do not have lightheadedness, shortness of breath, chest pain, or other severe symptoms. To do this maneuver, first lie down, take a deep breath and hold it, and then bear down as if you are having a bowel movement.

If you become quite lightheaded, you should lie down and call for assistance and for immediate transport to a local hospital. If transportation is not immediately available, or if you have chest pain or feel like you might lose consciousness, call 911 right away. You may be brought to the emergency department of a local hospital. There, an ECG will be performed and an intravenous line will be started. You may be given a small amount of a medication called adenosine that is quite effective in stopping the SVT. Adenosine may cause flushing, a hot sensation, and a sudden feeling of breathlessness for 30 seconds or less. It should be used with caution in patients with asthma. Other medications such as verapamil,  $\beta$ -blockers, or diltiazem may also be given intravenously.

### Additional Information

The North American Society of Pacing and Electrophysiology. Rapid heartbeat (tachycardia and fibrillation). Available at: [http://www.naspe-patients.org/patients/signs\\_symptoms/too\\_fast.html](http://www.naspe-patients.org/patients/signs_symptoms/too_fast.html). Accessed November 5, 2002.

National Heart, Lung, and Blood Institute. Facts about arrhythmias/rhythm disorders. Available at: <http://www.nhlbi.nih.gov/health/public/heart/other/arrhyth.htm>. Accessed November 5, 2002.

American Heart Association. Arrhythmia: patients and family. Available at: <http://216.185.112.5/presenter.jhtml?identifier=8>. Accessed November 5, 2002.

American Heart Association. Dr. Goodheart: Wolf-Parkinson-White syndrome. Available at: <http://216.185.112.5/presenter.jhtml?identifier=1000>. Accessed November 5, 2002.

American Heart Association. Arrhythmias. Available at: <http://216.185.112.5/presenter.jhtml?identifier=11077>. Accessed November 5, 2002.