

Circulation

JOURNAL OF THE AMERICAN HEART ASSOCIATION



Restenosis: Repeat Narrowing of a Coronary Artery: Prevention and Treatment

George Dangas and Frank Kuepper

Circulation 2002;105;2586-2587

DOI: 10.1161/01.CIR.0000019122.00032.DF

Circulation is published by the American Heart Association, 7272 Greenville Avenue, Dallas, TX 75214
Copyright © 2002 American Heart Association. All rights reserved. Print ISSN: 0009-7322. Online
ISSN: 1524-4539

The online version of this article, along with updated information and services, is
located on the World Wide Web at:

<http://circ.ahajournals.org/cgi/content/full/105/22/2586>

Subscriptions: Information about subscribing to *Circulation* is online at
<http://circ.ahajournals.org/subscriptions/>

Permissions: Permissions & Rights Desk, Lippincott Williams & Wilkins, a division of Wolters
Kluwer Health, 351 West Camden Street, Baltimore, MD 21202-2436. Phone: 410-528-4050. Fax:
410-528-8550. E-mail:
journalpermissions@lww.com

Reprints: Information about reprints can be found online at
<http://www.lww.com/reprints>

CARDIOLOGY PATIENT PAGE

Restenosis: Repeat Narrowing of a Coronary Artery

Prevention and Treatment

George Dangas, MD; Frank Kuepper, MD

Angioplasty is a safe and effective way to unblock coronary arteries. During this procedure, a catheter is inserted into the groin or arm of the patient and guided forward through the aorta and into the coronary arteries of the heart. There, blocked arteries can be opened with a balloon positioned at the tip of the catheter. Initially, angioplasty was performed only with balloon catheters, but technical advances have been made and improved patient outcome has been achieved with the placement of small metallic spring-like devices called “stents” (Figure 1) at the site of the blockage. The implanted stent serves as a scaffold that keeps the artery open.

Angioplasty and stenting techniques are widely used around the world and provide an alternative option to medical therapy and bypass surgery for improving blood flow to the heart muscle. There are, however, limitations associated with angioplasty and stenting, one of which is called “restenosis.”

What does restenosis mean?

Restenosis occurs when the treated vessel becomes blocked again. It usually occurs within 6 months after the initial procedure.¹ Compared with balloon angioplasty alone, where the chance of restenosis is 40%, stents reduce the chance of restenosis to 25%.^{2,3} Therefore, the majority of patients having angioplasty today are treated with stents. Restenosis can occur after the use of stents, and physicians refer to this as “in-stent restenosis.”

Why does in-stent restenosis happen?

When a stent is placed in a blood vessel, new tissue grows inside the stent, covering the struts of the stent. Initially, this

new tissue consists of healthy cells from the lining of the arterial wall (endothelium). This is a favorable effect because development of normal lining over the stent allows blood to flow smoothly over the stented area without clotting. Later, scar tissue may form underneath the new healthy lining. In about 25% of patients, the growth of scar tissue underneath the lining of the artery may be so thick that it can obstruct the blood flow and produce an important blockage. In-stent restenosis is typically seen 3 to 6 months after the procedure; after 12 months have passed uneventfully, it is rare.

Who is at high risk for in-stent restenosis?

Patients with diabetes are at increased risk for in-stent restenosis. Further important risk factors relate to the properties of the blocked artery and the pattern of scar tissue growth inside the artery; the more extensive the scar tissue growth, the worse the prognosis is.⁴

What are the symptoms of in-stent restenosis?

In-stent restenosis may produce symptoms that are very similar to the symptoms that initially brought the patient to the interventional cardiologist, such as chest pain triggered by exertion. Diabetic patients, however, may have fewer symptoms, atypical and unusual symptoms, or even no symptoms at all. Fortunately, a heart attack does not usually occur even if in-stent restenosis develops.

How can we detect in-stent restenosis?

After stenting of coronary arteries, patients should follow-up with their cardiologist at regular intervals.

When symptoms occur after the procedure, the cardiologist may recommend diagnostic tests (for instance, an exercise stress test) to evaluate whether the patient is likely to have developed in-stent restenosis or another coronary artery is blocked. If in-stent restenosis is a possibility, the cardiologist may refer the patient for a repeat cardiac catheterization (Figure 2).

From the Cardiovascular Research Foundation, Lenox Hill Heart and Vascular Institute, New York, NY (G.D.), and Charité, Humboldt-University, Berlin, Germany (F.K.).

Correspondence to George Dangas, MD, PhD, Cardiovascular Research Foundation, Lenox Hill Heart and Vascular Institute, 55 East 59th Street, 6th Floor, New York, NY, 10022. E-mail gdangas@crf.org
(*Circulation*. 2002;105:2586-2587.)

© 2002 American Heart Association, Inc.

Circulation is available at <http://www.Circulationaha.org>
DOI: 10.1161/01.CIR.0000019122.00032.DF




Figure 1. Size of an expanded coronary stent in relation to a dime. The stent is 18 mm in length and 3.5 mm in diameter.

Can in-stent restenosis be prevented?

Prevention of in-stent restenosis starts at the point of stent implantation. The physician's knowledge of appropriate stent placement is crucial. Some specialized centers may perform imaging with a special catheter from the inside of the vessel (ultrasound). This technique allows more accurate placement and expansion of stents⁵ and may aid in the prevention of restenosis. Drugs and vitamins administered either orally or intravenously have been tested for prevention of restenosis and in-stent restenosis, but have not been consistently shown to be helpful.

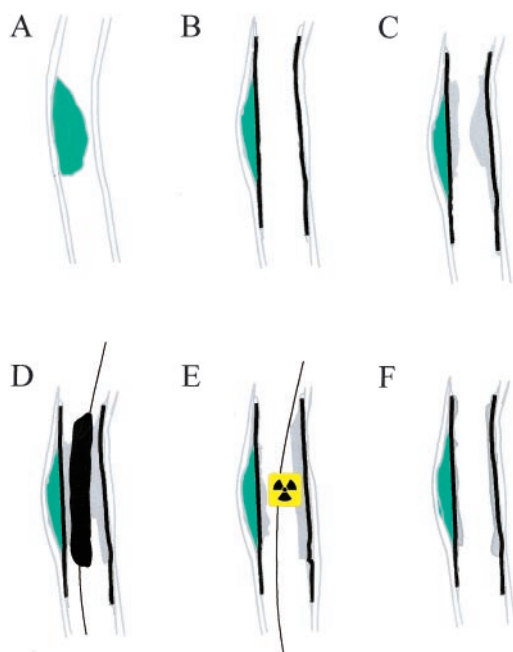


Figure 2. Development and treatment of in-stent restenosis. A, Coronary artery blocked by an atherosclerotic plaque. B, Unblocked coronary artery with an expanded stent. C, In-stent restenosis (scar tissue built up inside the stent). D, Balloon catheter in place to open coronary artery after occurrence of in-stent restenosis. E, Localized radiation therapy (brachytherapy) delivered to the location of in-stent restenosis by a special catheter to avoid recurrence of in-stent restenosis. F, Opened coronary artery after successful brachytherapy of in-stent restenosis. Drug-eluting stents prevent scar-tissue growth and may altogether obviate processes C through F.

New Techniques to Prevent Restenosis: Drug-Eluting Stents

During the last year, a breakthrough for the prevention of in-stent restenosis occurred in the form of a new generation of “drug-eluting” stents. These stents carry a special drug on their surface that prevents scar tissue growth in the artery where the stent is placed, and they therefore markedly reduce the occurrence of in-stent restenosis. Recent data demonstrated that patients treated with drug-eluting stents had decreased incidence of in-stent restenosis compared with those who received bare metal stents.⁶ Drug-eluting stents are not yet approved by the FDA, and the results of further studies are awaited.

How do we treat restenosis?

Repeat angioplasty or bypass surgery can be used to treat in-stent restenosis. In addition, local intravascular radiation (brachytherapy) can be used after treating in-stent restenosis with angioplasty to prevent recurrence.⁷ Brachytherapy uses a radioactive source that is delivered by a coronary artery catheter inside the narrowed artery for a short period of time (about 10 minutes). The source is removed and does not stay in the body. Because the short period of radiation inhibits long-term tissue growth in the treated vessel, it successfully prevents in-stent restenosis. Both β - and γ -irradiation are helpful in this setting.⁷ Only a few centers, however, have the special expertise needed to perform brachytherapy.

What can patients do to protect themselves?

After the procedure, patients should lead a heart-healthy lifestyle that includes a diet low in animal fat, regular exercise, blood pressure control, cessation of smoking, and minimal alcohol consumption. Regularly following-up with a cardiologist and taking medications as prescribed are also important preventive measures.

For additional discussion on in-stent restenosis, see www.heartcenteronline.com and www.tctmd.com.

References

1. Serruys PW, Luijten HE, Beatt KJ, et al. Incidence of restenosis after successful coronary angioplasty: a time-related phenomenon: a quantitative angiographic study in 342 consecutive patients at 1, 2, 3, and 4 months. *Circulation*. 1988;77:361–371.
2. Serruys PW, de Jaegere P, Kiemeneij F, et al. A comparison of balloon-expandable-stent implantation with balloon angioplasty in patients with coronary artery disease. Benestent Study Group. *N Engl J Med*. 1994; 331:489–495.
3. Fischman DL, Leon MB, Baim DS, et al. A randomized comparison of coronary-stent placement and balloon angioplasty in the treatment of coronary artery disease. Stent Restenosis Study Investigators. *N Engl J Med*. 1994;331:496–501.
4. Mehran R, Dangas G, Abizaid AS, et al. Angiographic patterns of in-stent restenosis: classification and implications for long-term outcome. *Circulation*. 1999;100:1872–1878.
5. Fitzgerald PJ, Oshima A, Hayase M, et al. Final results of the Can Routine Ultrasound Influence Stent Expansion (CRUISE) study. *Circulation*. 2000;102:523–530.
6. Sousa JE, Costa MA, Abizaid AC, et al. Sustained suppression of neointimal proliferation by sirolimus-eluting stents: one-year angiographic and intravascular ultrasound follow-up. *Circulation*. 2001;104: 2007–2011.
7. Leon MB, Teirstein PS, Moses JW, et al. Localized intracoronary gamma-radiation therapy to inhibit the recurrence of restenosis after stenting. *N Engl J Med*. 2001;344:250–256.